



# THE USE OF DIGITAL VENOGRAPHY FOR ASSESSMENT OF PERFUSION DEFICITS IN CHRONIC LAMINITIS

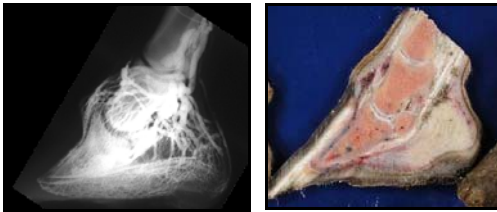


Elizabeth Arthur DVM, Amy Rucker DVM, University of Missouri-Columbia

## Problem

**Equine laminitis, or failure of the attachment between the distal phalanx and inner hoof wall, remains difficult to manage clinically**, largely because of an inability to predict the course of disease in an individual horse.<sup>1</sup> Laminitis is evaluated in terms of physical examination and radiographic findings, but little agreement exists regarding the prognostic significance of these findings. It has been suggested that the degree of pain experienced by the laminitic horse is the major determinant of outcome,<sup>2</sup> but subjective pain evaluation has also been found to predict the ultimate outcome in only 50% of cases.<sup>1</sup>

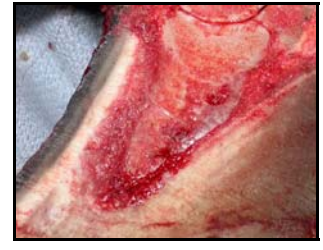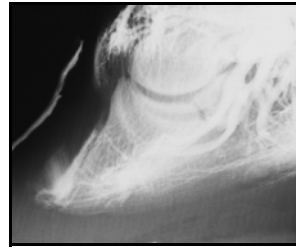
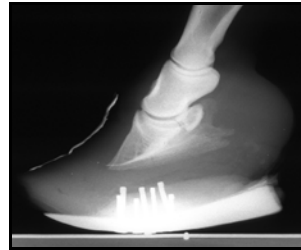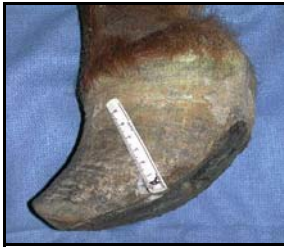The degree of distal phalangeal rotation is a standard tool for evaluation of the laminitic horse: the amount of rotation has been correlated inversely with prognosis,<sup>2</sup> but evidence also exists that the degree of rotation is not predictive for outcome of an individual horse.<sup>1,3</sup> Other factors that are considered significant signs of a poor prognosis, including acute laminitis lasting longer than ten days, coronary band separation, solar prolapse, and septic laminitis, have also been criticized as not useful for establishing prognosis in the management of a single patient.<sup>2,3</sup> Even distal displacement of the distal phalanx, which has been associated with greater than 50% mortality,<sup>1</sup> does not reliably predict poor outcome in one animal, since a correlation between the degree of displacement and the functional outcome has not been demonstrable.<sup>1</sup> The lack of consensus regarding the evaluation of laminitic horses suggests that additional diagnostic considerations may be necessary in order to accurately assess the ongoing disease process.



*A normal equine digit: venogram (left) compared to post-mortem sagittal section of the same foot (right), where blue latex is evident in both the arterial and venous circulation.*

**Digital venography is currently in use for evaluation of the laminitic foot**, but its prognostic significance has not yet been established, and criteria for interpretation remain in development. Perfusion deficits have been previously demonstrated in the feet of horses affected by chronic laminitis.<sup>4</sup> Circulatory status within the hoof may offer valuable information in accurately differentiating treatable from clinically refractory patients, because refractory patients have significantly worse vascular deficits than do other patients.<sup>4,5</sup> It is not possible to evaluate digital perfusion status using radiography alone, and the necessity of anesthesia makes digital angiography less clinically applicable.<sup>6</sup> Because the basic vascular pattern is consistent among the feet of normal horses, and injection into the digital vein results in retrograde filling of the arterial circulation, digital venography allows evaluation of digital perfusion in the standing horse.<sup>6</sup> It is clear that prognosis is a product of factors beyond the degrees of pain and rotation, therefore digital venography offers potentially valuable information in managing individual cases of laminitis.

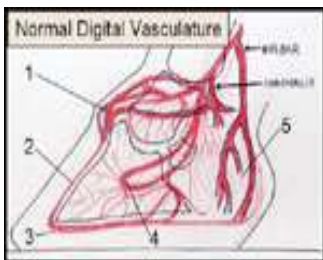
**We hypothesize that perfusion deficits will be evident in digital venograms from horses affected by chronic laminitis but will not be present in those from horses unaffected by laminitis.**



*A chronic laminitis foot affected by acute active laminitis. Far left: hoof conformation is grossly abnormal and characteristic of chronic laminitis; divergent growth rings and differential growth patterns are evident. Left: radiographic evidence of chronic laminitis includes rotation and remodeling of the distal phalanx and thickened dorsal hoof wall. Right: digital venography indicates compromised circumflex and dorsal lamellar vessel circulation, as well as leaking of contrast into the unstable dorsal lamellar scar. Far right: a post-mortem sagittal section of the same foot.*

## Methods

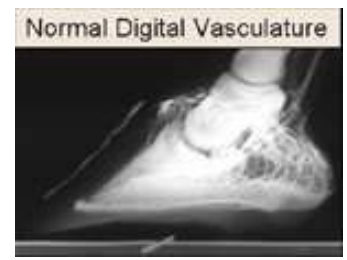Digital venograms both from horses unaffected by laminitis and from horses diagnosed independently of venogram findings with chronic laminitis were judged in a blinded study. The diagnosis of chronic laminitis was based on the presence of generally accepted physical or radiographic evidence of collapse of the foot architecture. These characteristic changes in hoof conformation include a thickened dorsal hoof wall; divergent growth rings on the hoof wall; widened white line; flattened or convex sole; and radiographic evidence of rotation, remodeling, or lysis of the distal phalanx.<sup>7</sup> Venograms were performed according to a standard technique<sup>8</sup> and assessed by four independent evaluators. Five major areas of digital perfusion were described as normal or abnormal: the coronary plexus, dorsal lamellar vessels, circumflex vessels, terminal arch, and heel perfusion.



*The normal equine digital vasculature anatomy is consistent among individuals.*

*Five major areas of equine digital perfusion:*

- (1) coronary plexus*
- (2) dorsal lamellar vessels*
- (3) circumflex vessels*
- (4) terminal arch*
- (5) heel perfusion*



## Results

**Perfusion deficits were identified in venograms from horses with chronic laminitis but were not present in the control group** of venograms from horses with healthy feet. These results are reminiscent of a published study in which the digital vasculature of normal horses was compared to that of laminitic horses post-mortem. Characteristic perfusion deficits were grossly evident in the laminitic vascular tree, while those of the normal horses closely resembled the equine foot's accepted normal vascular pattern.

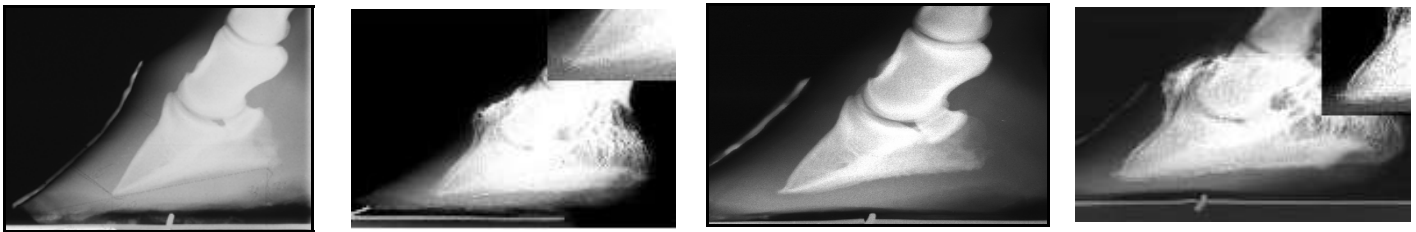
Each venogram was evaluated by multiple blinded readers: the five major regions of perfusion were graded individually as normal or abnormal.<sup>8</sup> Statistical analysis was performed using the Fischer test to evaluate the significance of scoring differences in each region between venograms from normal versus laminitic horses.<sup>9</sup>

**Significant differences between the normal and chronically laminitic groups** ( $p < 0.05$ ) were identified in the coronary plexus, dorsal lamellar vessels, and circumflex vessels. In all three areas, venograms from normal

horses were evaluated as having normal patterns of perfusion, while those from the chronically laminitic horses were perceived as being abnormally perfused.

The terminal arch and heel perfusion regions of venograms from clinically normal horses were consistently evaluated as having normal patterns of perfusion. However, interpretation of these regions on venograms from horses with chronic laminitis was not significantly different from those of normal horses. This finding is consistent with the previously published description of vascular deficits associated with chronic laminitis: these areas were compromised only in horses with severe disease refractory to treatment. While venograms comprising the experimental group in this project were exclusively from horses with clear evidence of chronic laminitis, the group included a broad spectrum of mildly affected to severely compromised feet. The venograms from chronically laminitic horses, therefore, could not reasonably be expected to demonstrate consistent perfusion deficits in the terminal arch or heel region.

The significant differences in venogram interpretation between normal and clinical groups suggest that digital venography is useful in identifying perfusion deficits in the laminitic horse.

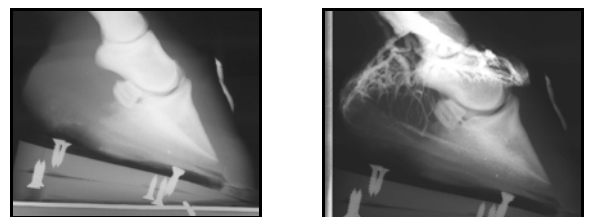


*Digital venography may be useful in monitoring the progression of disease or response to treatment over time. Far left: laminitis is evident with rotation of the distal phalanx; neither lysis nor remodeling is present. Left: a digital venogram is performed at the same time as the above radiograph and indicates that the third phalanx has displaced distal to the circumflex vessels resulting in a perfusion deficit. Right: the same foot is evaluated several months later, with bony remodeling present in addition to rotation of the distal phalanx. Far right: vascular changes are also evident at this time; circumflex vessels have remodeled around the tip of the distal phalanx.*

## Conclusions

**Disruption of the foot's vascular supply is important in the pathogenesis of chronic laminitis**, and digital venography offers a practical method for evaluation of circulation. Digital venography, then, may become a valuable tool in assessment of decreased perfusion associated with and contributing to chronic laminitis. Anecdotal evidence suggests that this additional information is valuable in establishing prognosis, which may not be adequately determined using traditional parameters that include degree of rotation of the distal phalanx and subjective impression of pain. It has been suggested that stark contrast loss in three areas: the lamellar vessels, circumflex area, and terminal arch, indicates a grave prognosis without immediate aggressive therapy. Ultimately, it may be possible to develop standardized methods of digital venogram interpretation in order to quantify the significance of perfusion deficits in the prognosis of chronic laminitis.

*An example of the prognostic value of digital venography: Left: the foot appears normal on plain film radiographs with mild thickening of the dorsal hoof wall; rotation and distal displacement of the distal phalanx are absent. Right: digital venography reveals profound perfusion deficits. Immediate aggressive therapy or euthanasia is indicated for this patient.*



## References

1. Hunt RJ. A retrospective evaluation of laminitis in horses. *Equine Vet J* 1993;25(1):61-64.
2. Stick JA, Jann HW, Scott EA, *et al.* Pedal bone rotation as a prognostic sign of laminitis of horses. *J Am Vet Med Assoc* 1982;180(3):251-253.
3. Cripps PJ, Eustace RA. Radiological measurements from the feet of normal horses with relevance to laminitis. *Equine Vet J* 1999;31(5):427-432.
4. Hood DM, Grosenbaugh DA, Slater MR. Vascular perfusion in horses with chronic laminitis. *Equine Vet J* 1994;26(3):191-196.
5. Redden RF. Possible therapeutic value of digital venography in two laminitic horses. *Equine Vet Educ* 2001;169-171.
6. Redden RF. A technique for performing digital venography in the standing horse. *Equine Vet Educ* 2001;172-178.
7. Morgan SJ, Grosenbaugh DA, Hood DM. The pathophysiology of chronic laminitis: pain and anatomic pathology. In: Hood DM. *The veterinary clinics of North America*. Philadelphia: WB Saunders, 1999;395-417.
8. Redden RF. The use of venograms as a diagnostic tool. *Proceedings of the 7<sup>th</sup> bluegrass laminitis symposium*. International Equine Podiatry Center, Versailles, Kentucky: 1-6.
9. Snedecor GW, Cochran WG. *Statistical Methods*, 8<sup>th</sup> ed. Ames, Iowa: Iowa State University Press, 1989.

### ***We gratefully acknowledge help from:***

*Brad Hill • Dan Renfro • Elaine Dziuban • Emily Elliott • Randy Holthusen • Ric Redden • Roberta Magai • Shannon Reed • Alice • Bertha • Brittany • Candace • Delilah • Dusty • Honey Pie • Lindy • Lisa • Magic • Man Down • Music • Q • Reba • Rushin' Brush • Sasha • Scotty • Sugar • Tomato • Two • Zap*